Medicine®

CLINICAL CASE REPORT

OPEN

Heterotopic Gastric Mucosa in the Distal Part of Esophagus in a Teenager

Case Report

Vasile Valeriu Lupu, MD, PhD, Ancuta Ignat, MD, PhD-student, Gabriela Paduraru, MD, PhD, Doina Mihaila, MD, PhD, Marin Burlea, MD, PhD, and Anamaria Ciubara, MD, PhD

Abstract: Heterotopic gastric mucosa (HGM) of the esophagus is a congenital anomaly consisting of ectopic gastric mucosa. It may be connected with disorders of the upper gastrointestinal tract, exacerbated by *Helicobacter pylori*. The diagnosis of HGM is confirmed via endoscopy with biopsy. Histopathology provides the definitive diagnosis by demonstrating gastric mucosa adjacent to normal esophageal mucosa. HGM located in the distal esophagus needs differentiation from Barrett's esophagus. Barrett's esophagus is a well-known premalignant injury for adenocarcinoma of the esophagus. Malignant progression of HGM occurs in a stepwise pattern, following the metaplasia–dysplasia–adenocarcinoma sequence.

We present a rare case of a teenage girl with HGM located in the distal esophagus, associated with chronic gastritis and biliary duodenogastric reflux. Endoscopy combined with biopsies is a mandatory method in clinical evaluation of metaplastic and nonmetaplastic changes within HGM of the esophagus.

(*Medicine* 94(42):e1722)

Abbreviations: CK = cytokeratin, COX = cyclooxygenase, HGM = heterotopic gastric mucosa.

INTRODUCTION

Heterotopic gastric mucosa (HGM) of the esophagus was first defined in 1805 by Schmit during a postmortem examination.[1] HGM of the esophagus is mostly localized in the upper esophagus and termed inlet patch.[2] An inlet patch is a congenital anomaly and most of these are largely asymptomatic. It usually cannot be diagnosed easily. Rarely, it can also be found in other parts of the esophagus.[3,4] HGM is reported in up to 10% of the general population among numerous reports and epidemiologic studies which have been essentially performed in adult population.[5] Pediatric data are still limited. There are case reports showing that this injury may play a role in the development of stenosis, ulcer, perforation, or esophagotracheal fistula related to its capability of hydrochloric acid secretion.[6,7] Malignant progression of HGM occurs in a stepwise pattern, following the metaplasia–dysplasia–adenocarcinoma sequence.[8,9] These complications may be exacerbated by *Helicobacter pylori*.[10]

We present a case of esophageal gastric heterotopia that was located in the distal esophagus and needed differentiation from Barrett's esophagus.

CASE REPORT

A Caucasian teenage girl, 16 years old, followed up for the last 3 years, was initially admitted in the V-th Pediatric Gastroenterology Clinic of ''St Mary'' Children's Emergency Hospital, Iasi, Romania, for postprandial epigastric pain.

Over the 3 years, her physical examination revealed good generally status, abdominal pain localized in the left hypochondrium and/or in epigastrium, without any other pathological elements at examination. The informed consent was obtained each time the patient was hospitalized.

Laboratory tests: complete blood count showed normal results.

The upper gastrointestinal endoscopy revealed the presence of multiple pseudo-polypoid formations with slightly eroded tip, measuring approximately 0.5 cm, in the lower 1/3 of esophagus (Fig. 1A, B); stomach with hypertrophic folds, with nodular purpuric congestion and erosions covered with hematic deposit in the antral region, sero-mucous fluid stasis of bile (Fig. 2), duodenum with diffuse congestion without ulceration, friable mucosa.

Histopathologic examination of the biopsy samples taken from the pseudo-polypoid formations showed acid-secreting, oxyntic-type, glandular, gastric epithelium, attached to the esophageal epithelium, without intestinal metaplasia or dysplasia. There were a few microhemorrhagic outbreaks and a discrete inflammatory infiltrate (Fig. 3A, B, C). Our histopathologic examination did not show intestinal metaplasia or Goblet cells (Alcian blue stain), which are important for the diagnosis of Barrett's esophagus. Five biopsy samples were taken, 3 from inlet patches which revealed gastric epithelium and 2 down (distal) from these injuries where squamous epithelium was found. These inlet patches were clearly separated from the stomach by squamous epithelium. The test was negative for *H. pylori*.

At colonoscopy, the mucosa of rectum, sigmoid and descending colon appeared normal, without evidence of diverticulosis or polyps.

DISCUSSIONS

HGM is a congenital defect that is usually no >1 cm. HGM can be <1 cm or >5 cm.[11] The inlet patch is considered an

Editor: Somchai Amornyotin.
Received: May 3, 2015; revised: September 9, 2015; accepted: September 11, 2015.
From the Pediatrics Department (VVL, AI, GP, MB), University of Medicine and Pharmacy ''Gr. T. Popa''; Pathology Department (DM), ''St Mary'' Children's Emergency Hospital; and Psychiatry Department (AC), University of Medicine and Pharmacy ''Gr. T. Popa,'' Iasi, Romania.
Correspondence: Ancuta Ignat, Pediatrics Department, University of Medicine and Pharmacy ''Gr. T. Popa,'' Str. Universitatii nr. 16, Iasi 700115, Romania (e-mail: anca_ign@yahoo.com).
The authors have no funding and conflicts of interest to disclose.
Copyright © 2015 Wolters Kluwer Health, Inc. All rights reserved.
This is an open access article distributed under the Creative Commons Attribution-NoDerivatives License 4.0, which allows for redistribution, commercial and non-commercial, as long as it is passed along unchanged and in whole, with credit to the author.
ISSN: 0025-7974
DOI: 10.1097/MD.0000000000001722

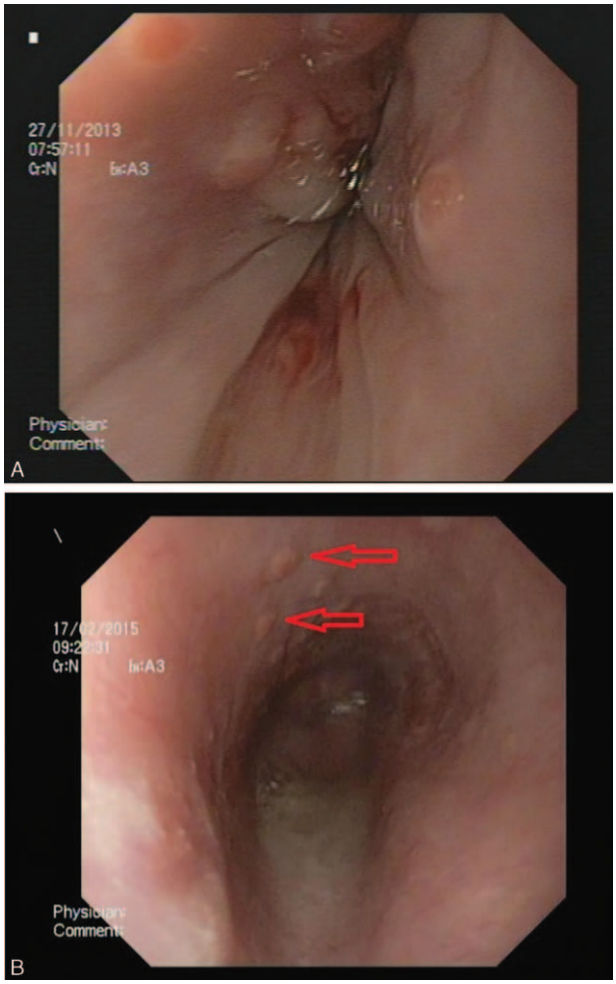

FIGURE 1. (A) Gastric heterotopia in the distal part of esophagus; (B) gastric heterotopia in the distal part of esophagus.

inherited anomaly. Inlet patches represent the incomplete transformation from columnar to squamous epithelium during embryonic development.[12] The process is starting from the middle third of the esophagus and extending proximally and distally. The last esophageal segment reepithelialized is the most proximal. HGM develops on incomplete reepithelialization. The persisting columnar cells at birth are usually proximally over the upper third of the esophagus or, much less frequently, distally over the esophagogastric junction. The preferential localization of HGM in the cervical esophagus is explained by the temporal difference in the stratified reepithelialization of both ends of the esophagus.[13]

It is generally accepted that Barrett's esophagus is an acquired metaplastic change because of chronic gastroesophageal reflux. Another proposed theory on the development of HGM involves metaplastic transformation of the squamous lining to columnar from chronic acid injury as seen in Barrett's esophagus.[14] These are based on similarities in the mucin and staining characteristics with CK7 and CK20 between Barrett's esophagus and HGM.[15] It is postulated that chronic acid exposure results in inflammation that leads to reactivation or proliferation of remnant columnar mucosa. These remnants of columnar mucosa are present as microscopic foci in the esophageal lining or are covered by squamous mucosa. With

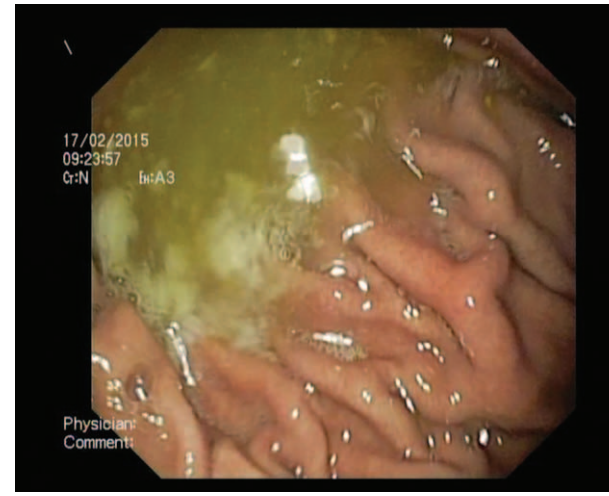

FIGURE 2. Nodular purpuric gastritis with hypertrophic folds; biliary reflux.

chronic irritations, these foci develop into larger patch resulting in the formation of island of columnar mucosa, HGM.[16]

It was also proposed that the origins of HGM may be different, congenital in children and acquired in adult.[15]

There are several factors that favor the congenital origin hypothesis. The embryogenesis of esophagus can explain the profiles of HGM, proximal location or the distal part of the esophagus. The children do not have sufficient duration of acid exposure to induce changes suggested by the acquired theory.

The origin of esophageal HGM has not been finally determined as yet, and further investigations are needed to resolve these questions.[3] But from current available evidence, it seems more likely that HGM is congenital in origin.

Most inlet patches are solitary and extend longitudinally. In the patients with multiple patches, they tend to be small.[17] In our case, we have described them as multiple pseudo-polypoid formations with slightly eroded tip.

Most inlet patches are clinically asymptomatic.[18] The underlying factor of the symptoms, clinical findings, and complications is the secretion of acid. Only in 10% of cases they do produce clinical symptoms, such as chest and throat pain, dysphagia, globus sensation, shortness of breath, chronic cough and hoarseness.[19] In our case, the patient presented with postprandial epigastric pain only. In our patient, HGM was associated with discrete inflammation, chronic gastritis, and biliary duodenogastric reflux. The HGM was grade I according to the proposed clinicopathologic classification (Table 1).[3]

Ectopic gastric mucosa can occur anywhere along the gastrointestinal tract. For this reason, we performed the colonoscopy which was normal.

Barrett's esophagus is characterized histologically by an admixture of 3 columnar epithelia: cardiac, oxyntocardiac, and intestinal metaplasia. Histologically, HGM consists of oxyntic mucosa with mucus-secreting columnar cells, chief cells, and parietal cells.[3]

Barrett's esophagus is widely considered to be a consequence of longstanding acid induced injury commencing as an erosive esophagitis and progressing over years to columnar and intestinal metaplasia of the squamous epithelium. In our case, the patient had biliary duodenogastric reflux, without esophagitis. It needed a histopathologic confirmation, that is the presence of intestinal metaplasia.[20] Our histopathologic examination revealed

Copyright © 2015 Wolters Kluwer Health, Inc. All rights reserved.

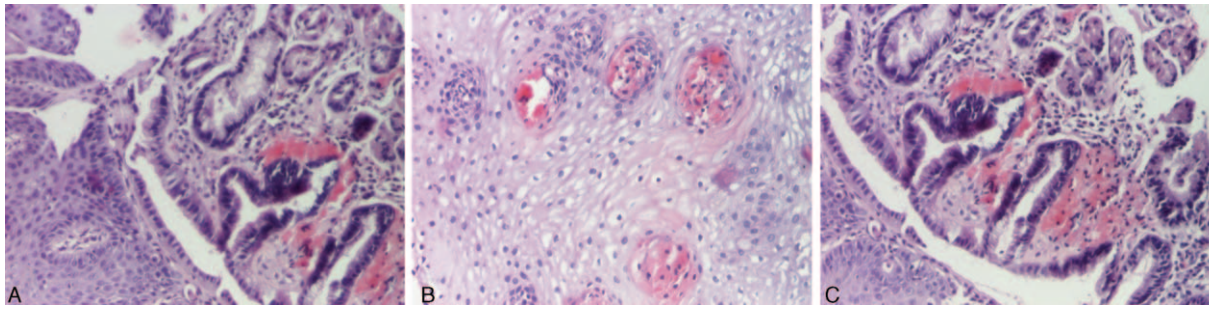

FIGURE 3. Histopathologic examination (histopathologic examination [HE] × 100): A—gastric epithelium attached to the esophageal epithelium. B—inflammation and microhemorrhages in the esophageal epithelium. C—inflammation and microhemorrhages in the gastric epithelium.

just a discrete inflammatory infiltrate, without intestinal metaplasia or dysplasia. In Barrett's esophagus, columnar epithelium extends from the stomach up to the gastroesophageal junction into the esophagus.[20] It looks like a continuation of gastric mucosa. In our case, columnar epithelium was not the continuation of gastric mucosa; it was clearly separated from the stomach by squamous epithelium. There were multiple pseudo-polypoid formations, which can indicate that all lesions are congenital and not reflux related as in Barrett's esophagus. Furthermore, over the last 3 years as we have followed up the patient, the injuries have remained the same in number and pathology. Based on studies from the literature, we reevaluated the findings in our patient as gastric heterotopia and not Barrett's esophagus.

A strong affinity of *H. pylori* to colonize gastric type mucosa has been demonstrated.[21] In our case, colonization of HGM and of stomach with *H. pylori* was not observed.

This type of gastric heterotopia can cause reflux-like symptoms, which resolved very well with proton pump inhibitor treatment.[22] No treatment is required for asymptomatic HGM.

Strictures are treated with serial dilatation and should be biopsied to rule out malignancy.

It can be discussed about an ablation of the gastric heterotopia's area. We did not try it because of the lack of support in the literature.

The cyclooxygenase (COX) enzyme catalyzes the conversion of arachidonic acid to prostaglandins.[23] There are 2 COX isoforms in humans: COX-1 and COX-2. Overexpression of COX-2 has numerous effects on cells: increased cell proliferation, decreased apoptosis rate, stimulation of angiogenesis, and increased invasive and metastatic potential.[24,25] Neoplastic transformation in gastric heterotopia is rare. In contrast to Barrett's esophagus, gastric heterotopia has not been accepted as a premalignant lesion.[3] COX-2 is overexpressed in Barrett's esophagus and is involved in the sequence of events that lead to malignant transformation.[26]

We are following the evolution by endoscopy every 6 months and multiple esophageal biopsies once a year in order to monitor any change in HGMs.

TABLE 1. Clinicopathologic Classification of Esophageal HGM

HGM I	Asymptomatic
HGM II	Symptomatic without morphologic changes (dysphagia/odynophagia)
HGM III	Symptomatic with morphologic changes (benign complications: strictures, ulcers, webs, stenoses, fistula)
HGM IV	Intraepithelial neoplasia (dysplasia) (low-grade/high-grade)
HGM V	Invasive adenocarcinoma
Suffix	
a.	= inlet patch (macroscopically visible patch of HGM)
b.	= microscopic foci (only microscopically visible HGM)

HGM = heterotopic gastric mucosa.

CONCLUSIONS

We are presenting a case with multiple pseudo-polypoid formations of gastric heterotopia that are located in the distal part of the esophagus. HGM should not be overlooked in the diagnostics. Endoscopy combined with histopathologic and microbiological analysis of biopsies is definitely a mandatory method in clinical evaluation of metaplastic and nonmetaplastic changes within HGM of the esophagus.

When, during superior digestive endoscopy, columnar-lined esophagus is observed in the distal esophagus, not being in continuity with gastric mucosa, the diagnosis of HGM must be thought and confirmed histologically by the presence of pure oxyntic mucosa.

REFERENCES

1. Tang P, McKinley MJ, Sporrer M, et al. Inlet patch: prevalence, histologic type, and association with oesophagitis, Barrett oesophagus, and antritis. *Arch Path Lab Med.* 2004; 128:444–447.
2. Chong VH. Heterotopic gastric mucosal patch of the proximal oesophagus. In: Pascu O, ed. *Gastrointestinal Endoscopy.* Croatia: InTech Publishing; 2011:125–148.
3. Von Rahden BH, Stein HJ, Becker K, et al. Heterotopic gastric mucosa of the esophagus: literature-review and proposal of a clinicopathologic classification. *Am J Gastroenterol.* 2004;99:543–551.
4. Borhan-Manesh F, Farnum JB. Incidence of heterotopic gastric mucosa in the upper oesophagus. *Gut.* 1991;32:968–972.
5. Tanpowpong P, Katz AJ. Heterotopic gastric mucosa causing significant esophageal stricture in a 14-year-old child. *Dis Esophagus.* 2011;24:E32–E34.
6. Azar C, Soweid A. Inlet patch: the ''under-explored'' island. *J Clin Gastroenterol.* 2009;43:97–98.

Copyright © 2015 Wolters Kluwer Health, Inc. All rights reserved.

7. Rosztóczy A, Izbéki F, Németh IB, et al. Detailed esophageal function and morphological analysis shows high prevalence of gastroesophageal reflux disease and Barrett's esophagus in patients with cervical inlet patch. *Dis Esophagus.* 2012;25:498–504.
8. Noguchi T, Takeno S, Takahashi Y, et al. Primary adenocarcinoma of the cervical esophagus arising from heterotopic gastric mucosa. *J Gastroenterol.* 2001;36:704–709.
9. Komori S, Osada S, Tanaka Y, et al. A case of esophageal adenocarcinoma arising from the ectopic gastric mucosa in the thoracic esophagus. *Rare Tumors.* 2010;2:12–15.
10. Gutierrez O, Akamatsu T, Cardona H, et al. Helicobacter pylori and heterotopic gastric mucosa in the upper esophagus (the inlet patch). *Am J Gastroenterol.* 2003;98:1266–1270.
11. UyanIkoğlu A, Coşkun M, Binici DN, et al. Giant inlet patch in cervical oesophagus. *Endoscopy.* 2011;19:75–76.
12. Maconi G, Pace F, Vago L, et al. Prevalence and clinical features of heterotopic gastric mucosa in the upper oesophagus (inlet patch). *Eur J Gastroenterol Hepatol.* 2000;12:745–749.
13. Chong VH. Clinical significance of heterotopic gastric mucosal patch of the proximal esophagus. *World J Gastroenterol.* 2013;19:331–338.
14. Avidan B, Sonnenberg A, Chejfec G, et al. Is there a link between cervical inlet patch and Barrett's esophagus? *Gastrointest Endosc.* 2001;53:717–721.
15. Lauwers GY, Mino M, Ban S, et al. Cytokeratins 7 and 20 and mucin core protein expression in esophageal cervical inlet patch. *Am J Surg Pathol.* 2005;29:437–442.
16. Vui Heng Chong. Heterotopic gastric mucosal patch of the proximal esophagus. Available at http://cdn.intechopen.com/pdfs-wm/24189.pdf. Last accessed in 13.08.2015.
17. Day DW, et al. Morson and Dawson's Gastrointestinal Pathology. 4th ed. Malden, MA: Blackwell; 2003.
18. Shu-Jung T, Ching-Chung L, Chen-Wang C, et al. Benign esophageal lesions: endoscopic and pathologic features. *World J Gastroenterol.* 2015;21:1091–1098.
19. Basseri B, Conklin JL, Mertens RB, et al. Heterotopic gastric mucosa (inlet patch) in a patient with laryngopharyngeal reflux (LPR) and laryngeal carcinoma: a case report and review of literature. *Dis Esophagus.* 2009;22: E1–E5.
20. American Gastroenterological AssociationSpechler SJ, Sharma P, et al. . American Gastroenterological Association medical position statement on the management of Barrett's esophagus. *Gastroenterology.* 2011;140:1084–1091.
21. Alagozlu H, Simsek Z, Unal S, et al. Is there an association between Helicobacter pylori in the inlet patch and globus sensation? *World J Gastroenterol.* 2010;16:42–47.
22. Zeynel Mungan. Is it Barrett's esophagus or gastric heterotopia? *Case Rep Gastroenterol.* 2014;8:282–285.
23. Eberhart CE, Dubois RN. Eicosanoids and the gastrointestinal tract. *Gastroenterology.* 1995;109:285–301.
24. Von Rahden BH, Stein HJ, Puhringer F, et al. Coexpression of cyclooxygenases (COX-1, COX-2) and vascular endothelial growth factors (VEGF-A, VEGF-C) in esophageal adenocarcinoma. *Cancer Res.* 2005;65:5038–5044.
25. Saukkonen K, Rintahaka J, Sivula A, et al. Cyclooxygenase-2 and gastric carcinogenesis. *APMIS.* 2003;111:915–925.
26. Lagorce C, Paraf F, Vidaud D, et al. Cyclooxygenase-2 is expressed frequently and early in Barrett's oesophagus and associated adenocarcinoma. *Histopathology.* 2003;42:457–465.

Copyright © 2015 Wolters Kluwer Health, Inc. All rights reserved.