ORIGINAL PAPER

RJME
Romanian Journal of Morphology & Embryology
http://www.rjme.ro/

Phyllodes tumor: diagnostic imaging and histopathology findings

ALINA CRISTIANA VENTER[1)], ELENA ROŞCA[1)], LUCIA GEORGETA DAINA[2)], GABRIELA MUŢIU[1)], ADRIANA NICOLETA PIRTE[3)], DANIELA RAHOTĂ[1)]

[1)]*Department of Morphological Sciences, Faculty of Medicine and Pharmacy, University of Oradea, Romania*
[2)]*Department of Neurosciences, Faculty of Medicine and Pharmacy, University of Oradea, Romania*
[3)]*Department of Dentistry, Faculty of Medicine and Pharmacy, University of Oradea, Romania*

Abstract

Phyllodes tumors are rare breast tumors, accounting for less than 1% of all primary tumors of the breast. Histologically, phyllodes tumors can be divided into benign (60%), borderline (20%) and malignant (20%). The mammography examination was performed by means of a digital mammography system Giotto 3D Images; the ultrasound examination was performed through a GE Logiq P6 device and histological confirmation was possible after surgery or following the histological biopsy. We grouped the nine patients who presented clinically palpable nodules into two groups, namely: the six patients presenting histological benign results into Group I, and Group II where we included those with borderline and malignant histological results. Mammography performed in 77.7% revealed a well-circumscribed round or oval opacity or with contour lobules. Ultrasound examination was performed in all patients. Mammography and ultrasound have limitation in differentiating between benign lesion and phyllodes tumor. In the nine analyzed cases, mammographic and ultrasound examinations did not allow the differentiation into the three groups of phyllodes tumor. Histopathological examination is considered the golden standard for their diagnosis. Correlations between mammographic and microscopic aspects were inconclusive for determining the degree of differentiation, ultrasound changes could be correlated with the histopathological aspects.

Keywords: phyllodes tumor, mammography, ultrasound examination, histopathological features.

Introduction

Phyllodes tumor belongs to the fibroepithelial tumors group, which combines epithelial lesions with mesenchymal lesions [1, 2]. There is a group of circumscribed biphasic fibroepithelial tumors characterized by an epithelial component arranged in clefts surrounded by a hypercellular mesenchymal component that is typically organized in a leaf like pattern [3].

They are rare breast tumors, accounting for less than 1% of all primary tumors of the breast and 2.5% of fibroepithelial tumors [4, 5]. They occur at any age, with a higher frequency in women in the fourth decade of their life, with an early onset in Asian countries (average age 25–30 years) [6, 7]. Although only 5% occur in women less than 20 years, they are considered most common breast cancers in young patients [8].

Histologically, phyllodes tumors can be divided into benign (60%), borderline (20%) and malignant (20%) [2]; the criteria which dictates the aforementioned classification are as follows: the nature of the tumor margins, increased connective tissues, mitoses and atypical stromal cellular [9, 10]. There are two groups of phyllodes tumors after Farid Moinfar: low-grade tumors with "pushing" margin, mild cytological atypia (<3 mitotic figures/10 HPF – high-power fields) – it has potential for local recurrence, but it is very unlikely to metastasize; and high-grade (malignant) tumors (malignant phyllodes tumors and cystosarcoma phyllodes) infiltrating or pushing margin, moderate to severe nuclear atypia, >3 mitotic figures/10 HPF [2, 3].

According to the literature, mammography and ultrasonography are not able to distinguish benign from malignant lesions [11, 12]. Yabuuchi *et al.* believe that some magnetic resonance (MR) features may suggest the phyllodes tumor histology [13]. However, the exact histological nature cannot be established based on MR breast appearance [14].

Aim

We report the cases of nine patients with breast nodules, examined in the Department of Imaging, Emergency County Hospital, Oradea, Romania, presenting their mammographic and ultrasound aspects in conjunction with their histopathological aspects.

Materials and Methods

The mammography examination was performed by means of a digital mammography system Giotto 3D Images, practicing the two standard incidents, *i.e.*, CC (craniocaudal) and MLO (mediolateral oblique); the ultrasound examination was performed with a GE Logiq P6 device with a 7–13 MHz linear transducer and elastography option, according to classical technique of breast examination.

The biopsies were taken in the Department of General Surgery, Emergency County Hospital, Oradea.

We had performed the histological examination in the Department of Pathology of the same Hospital by using specimens from incisional biopsy (three cases) and from surgery (excisional biopsy in six cases).

The fresh specimens were fixed in 10% neutral buffered formalin for at least 12–24 hours. The excisional biopsies were oriented, inked (for resection margins) and gross examined. We used the semiautomated Leica TP 1020 tissue processor, and we embedded samples in paraffin. The 5 µm sections were made using a manual HM 325 rotary microtome. The slides were stained with classical Hematoxylin–Eosin (HE) technique and then examined with Nikon Eclipse E600 light microscope. The pictures were taken using Nikon Coolpix 4500 camera.

The Informed Consent of Patient is written on the "Medical document of biopsy".

We have the agreement of Medical Ethics Commission.

The patients were submitted to surgical operation in the Department of General Surgery, Emergency County Hospital, Oradea.

Results

The nine women aged 19–72 years had an average age of 45.5 years. All presented clinically palpable nodules, six (66.6%) of them were benign phyllodes tumor, two (22.2%) of them were borderline tumors and one was malignant. We grouped the nine patients into two groups, namely: the six patients presenting histopathological (HP) benign results into Group I, and Group II where we included those with borderline and malignant HP results.

Mammography performed in seven (77.7%) patients revealed a well-circumscribed round or oval opacity in four cases or with lobulated contour in three cases (Figures 1–3).

Ultrasound examination was performed in all patients.

In the group of benign lesions, which presented a 3.6 cm average size, the appearance was round or oval, homogeneous, hypoechogenic lesion, going in parallel, with the posterior acoustic enhancement, with circumscribed margins and with increased intralesional vascularity (Figures 4–6).

In the group of malignant lesions of 4.8 cm average size, ranging 3.5 to 7.5 cm, hypoechogenic lesion appearance was irregular with micro-lobules edges and heterogeneous echotexture presenting cystic or necrotic degeneration predominant areas, and with hyperintensity at Doppler examination (Figure 7).

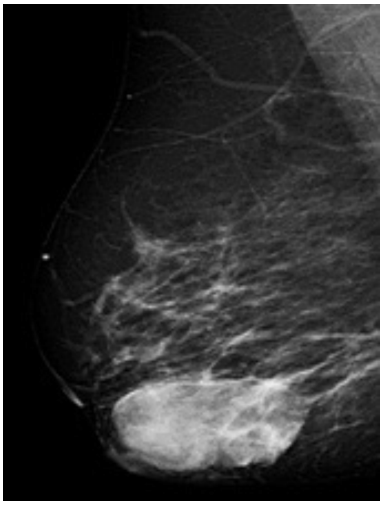

Figure 1 – ***Mediolateral oblique (MLO) mammogram shows in the right lower quadrant a well-circumscribed oval opacity – benign phyllodes tumor.***

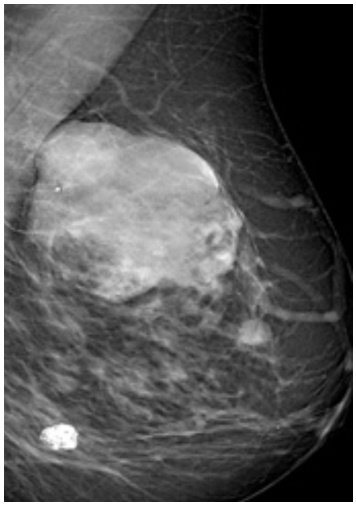

Figure 2 – ***MLO mammogram shows in the left upper quadrant an opacity with lobulated contour – benign phyllodes tumor.***

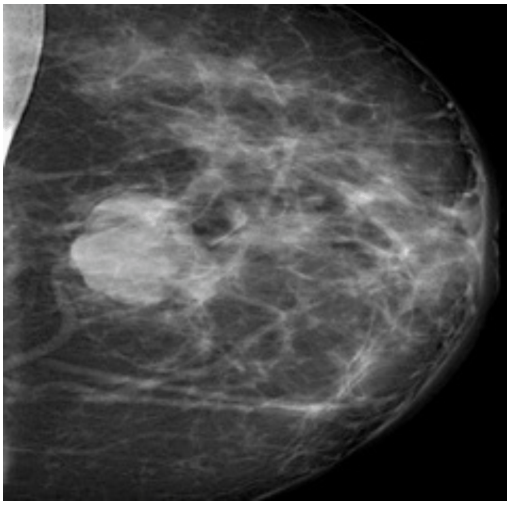

Figure 3 – ***Craniocaudal (CC) mammogram shows in the upper quadrants a well-circumscribed opacity partially lobulated contour – benign phyllodes tumor.***

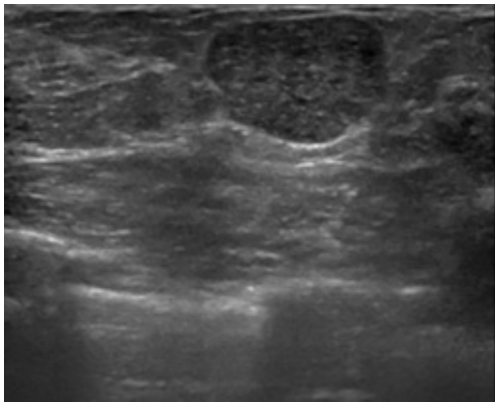

Figure 4 – ***Ultrasound image shows a hypoechogenic lesion, homogeneous, with circumscribed margins – benign phyllodes tumor.***

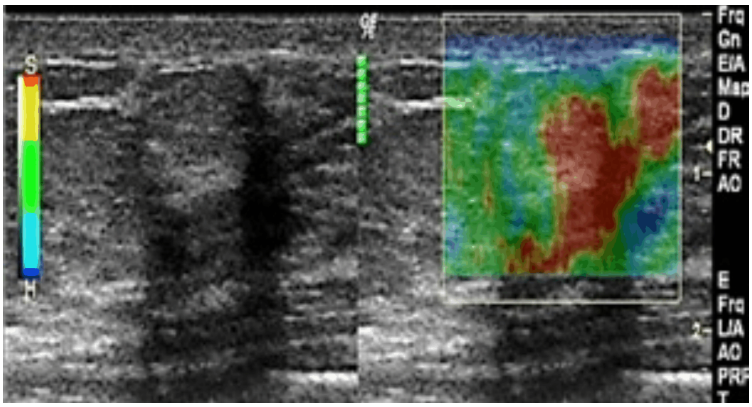

Figure 5 – ***Ultrasound image shows a hypoechogenic lesion with elastographic score 1 (benign).***

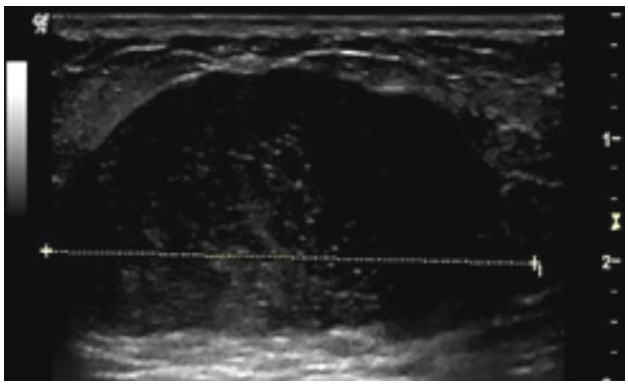

Figure 6 – ***Ultrasound image shows a hypoechogenic homogeneous, well-defined, lobular lesion, with posterior acoustic enhancement – benign phyllodes tumor.***

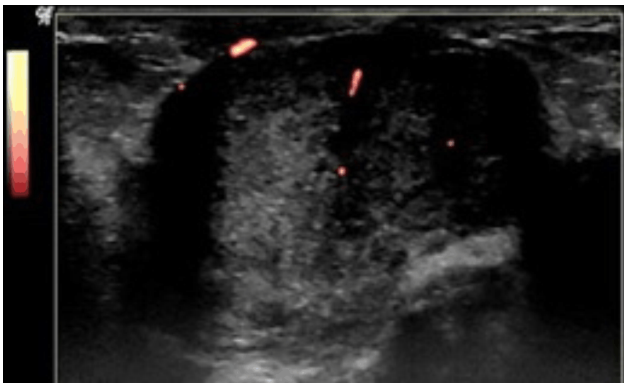

Figure 7 – ***Ultrasound image shows a hypoechogenic lesion with heterogeneous echostructure with hyperintensity at Doppler examination – borderline phyllodes tumor.***

Histologically, phyllodes tumors are composed of lactiferous ducts lined by epithelial and myoepithelial cells surrounded by a stromal spindle cells with monomorphic nuclei and rare mitoses, "leaf-like" stroma protruded into cystic spaces (ducts) and more cellular around ducts. They are myxoid areas, areas with hyaline at stromal level. Bizarre cells may be present yet not a sign of malignancy. In the literature, there have been reported areas of fibrous, cartilaginous, bone tissues and/or muscle in stroma.

The three categories – benign, borderline and malignant – have characteristics by stromal cellularity, cellular pleomorphism, mitotic activity, margins, percentage of metastasis and relapse rate.

There are two groups of phyllodes tumors: low-grade tumors with "pushing" margin, mild cytological atypia (<3 mitotic figures/10 HPF) (Figures 8–10); and high-grade (malignant) tumors (malignant phyllodes tumors and cystosarcoma phyllodes) infiltrating or pushing margin, moderate to severe nuclear atypia, >3 mitotic figures/10 HPF (Figure 11).

The borderline group of tumors is characterized by microscopic invasion areas around the margins edges, 2–5 mitoses/10 HPF, moderate stromal cellularity, heterogeneous hypocellular areas (Figure 12).

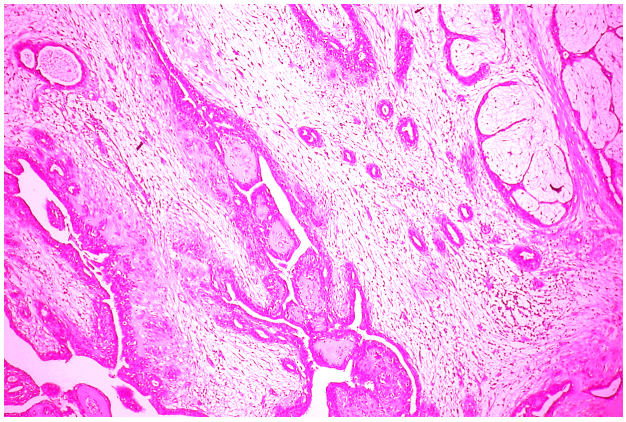

Figure 8 – ***Phyllodes tumor: biphasic pattern with benign epithelial component and an associated cellular and myxoid stroma. HE staining, ×40.***

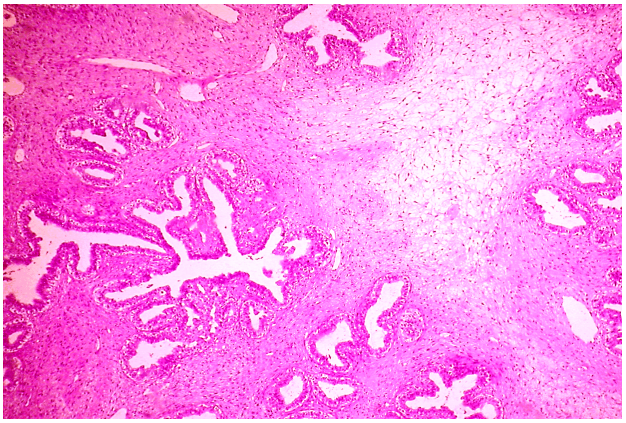

Figure 9 – ***Phyllodes tumor: focal epithelial hyperplasia with a leaf-like appearance in a cellular stroma with areas of myxoid differentiation. HE staining, ×40.***

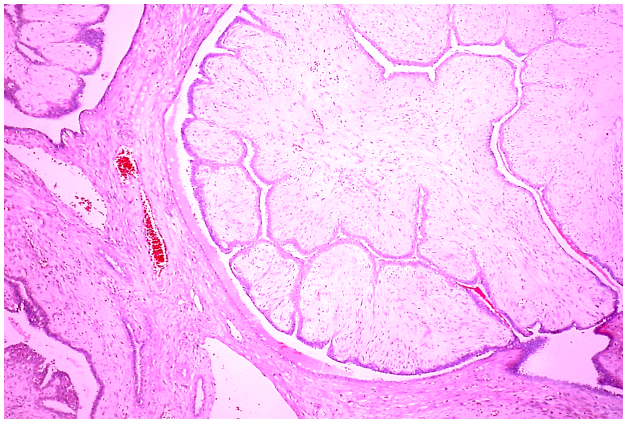

Figure 10 – ***Phyllodes tumor: epithelial hyperplasia with staghorn-like shape reminding of fibroadenoma with intracanalicular growth pattern in a well-defined stroma. HE staining, ×40.***

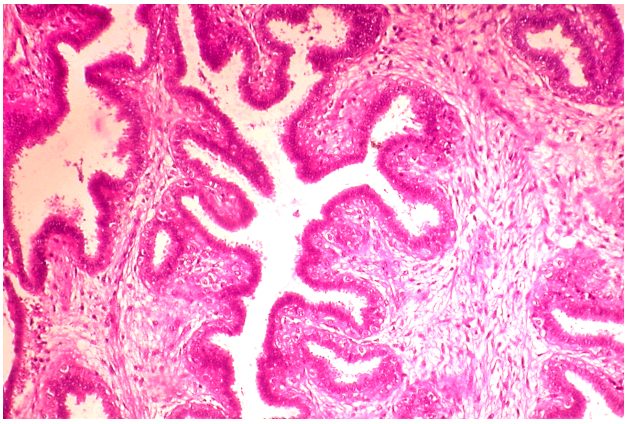

Figure 11 – ***Phyllodes tumor: florid epithelial hyperplasia with layers of myoepithelial cells and luminal epithelial cells in a myxoid stroma with pleomorphic cells. HE staining, ×100.***

Figure 12 – ***Borderline phyllodes tumor: focal epithelial hyperplasia, a highly cellular stroma with pleomorphism and nuclear atypia. HE staining, ×200.***

Discussion

Imaging and histopathological features

At the mammography, phyllodes tumor usually manifests as a round, oval or multilobate shaped, calcifying, fine edged lump. Tumor sizes vary from small tumor to large masses occupying virtually the entire mammary gland. Mammography issues are significantly overlapping issues between phyllodes tumor and benign lesions such as fibroadenomas [11, 15].

Similarly, fibroadenoma is an oval or lobular shaped mass, homogeneous with clear edges. By contrast, fibroadenoma may present peripheral calcification ("popcorn") which, in time, comes to include the entire lesion. However, if a mammogram shows a circumscribed net mass over 6–8 cm in diameter or if a solid lesion shows rapid growth on serial mammograms, one should raise the suspicion of phyllodes tumor [4, 8, 16].

In adolescents, it is difficult to distinguish between the giant juvenile fibroadenomas and phyllodes tumor given that both tumors have the same mammographic appearance of rapidly growing masses [15, 17].

Even in the case of ultrasounds examination, the appearance of phyllodes tumor may be similar to fibroadenomas. As the latter, the phyllodes tumor has the appearance of a hypoechogenic homogeneous, well-defined, oval or lobular shaped lesion [12].

However, phyllodes tumor occurs frequently with heterogeneous echostructure with irregular walls, with partial transonic content and with posterior acoustic enhancement and septa. These are characteristics of phyllodes tumor and they are rarely visible in fibroadenomas [15, 18].

Mammography and ultrasonography have limitations in differentiating between benign lesions and phyllodes tumor and they cannot specify its histological grade.

The clinical course is unpredictable regardless the histological grade. The current histological classification and radiological features face difficulties in predicting the clinical behavior including the development of local recurrence, distant metastasis and survival rate [9, 19]. Histopathological confirmation is made ideally on the surgical excision sample [20, 21].

The etiology is still unknown [5, 8]. Phyllodes tumor may develop *de novo* or from a fibroadenoma or adjacent to a fibroadenoma [8, 15].

The most common clinical occurrence is a mobile, painless, palpable and growing fast node [2, 5]. This finding in middle-aged and older women suggests rather phyllodes tumor and not fibroadenomas [15, 22]. The tumor mass may be 10 cm or greater, with an average diameter of 5 cm; they are rarely multifocal or bilateral [8, 23].

Ulceration of the skin or chest wall invasion may occur in patients with very large phyllodes tumors [5, 15]. Affecting lymph nodes is rare, therefore the axillary lymph node staging is usually not necessary [5, 8, 21].

Macroscopically, they are well-circumscribed, firm tumors on the gray and mucoid, homogeneous or cystic surface. In large tumors, areas of hemorrhage and necrosis may be present [6, 24]. Tumors may be larger than 10 cm more frequently (ranging between 1–45 cm); they can be rarely multifocal and bilateral [25, 26].

Cytopathology of phyllodes tumor includes variable cellularity, biphasic pattern (cohesive clusters of epithelial/myoepithelial cells with a background of numerous stromal cells; cellular stromal component with large spindle cells, variable cytological atypia of stromal cells [3, 27].

Microscopic features are characterized by biphasic (fibroepithelial neoplasm, showing stromal proliferation around glands (pericanalicular) or compressed cleft-like ducts (intracanalicular pattern) [10]. The ducts are lined by two cell layers (epithelial and myoepithelial cells), focal, leaf-like processes, stroma not hypercellular or/and squamos metaplasia and apocrine metaplasia [10, 16]. Stroma is distinguished by hypercellularity, myxoid, mucinous change or/and atypical and bizarre multinucleated giant cells or/and chondroid, osseous and smooth muscle metaplasia can very rarely occur [1, 2, 16].

The benign group, characterized by marked/slow cell growth, moderate/low cellular pleomorphism, has no metastases and the local recurrence rate after excision is 20% [9, 28, 29].

The group of malignant tumors, which represent 5–25% of phyllodes tumors, is characterized by marked stromal hypercellularity, more than 5 mitoses/10 HPF, invasive edges; less than 20% are accompanied by metastases in the lung, pleura, bone, liver and lymph node (rarely) [9, 27].

Approximately 30% of phyllodes tumors develop recurrences within two years after the diagnosis [21, 30]. The recurrences are common in malignant and borderline

phyllodes tumors; local recurrence and distant metastasis are rare in the case of benign forms. Recurrences trend is towards the same histological grade, although in 25% of patients one observes shifting to a higher grade [21, 28]. Local recurrence rate depends on the margin width of safety surgical excision, so that all histological types require a wide surgical excision [20, 21].

The malignant stromal component of phyllodes tumor is often fibrosarcomatous and rare liposarcoma, osteosarcoma, rhabdomyosarcoma, malignant fibrous histiocytoma [30, 31].

The behavior of phyllodes tumor is unpredictable; it is important to keep in mind that no single histopathological feature could reliably predict the behavior and combination of tumor size, margin, atypia, stromal overgrowth; mitotic activity would be helpful as a guide for histological behavior.

Conclusions

Mammography and ultrasound have limitation in differentiating between benign lesion and the phyllodes tumor. In the nine analyzed cases, mammographic and ultrasound examinations did not allow the differentiation into the three groups of phyllodes tumor. Histopathological examination is considered the golden standard for their diagnosis. Correlations between mammographic and microscopic aspects were inconclusive for determining the degree of differentiation, ultrasound changes could be correlated with the histopathological aspects.

Conflict of interests

The authors declare that they have no conflict of interests.

References

[1] Azzopardi JG, Ahmed A, Millis RR. Problems in breast pathology. W.B. Saunders, London–Philadelphia, 1979, 354–355.

[2] Tavassoli FA, Devilee P (eds). Pathology and genetics of tumours of the breast and female genital organs. World Health Organization (WHO) Classification of Tumours, International Agency for Research on Cancer (IARC) Press, Lyon, 2003, 99–103.

[3] Moinfar F. Essentials of diagnostic breast pathology: a practical approach. Springer-Verlag, Berlin–Heidelberg, 2007, 321–351, 444.

[4] Heywang-Köbrunner SH, Schreer I, Dershaw DD. Diagnostic breast imaging: mammography, sonography, magnetic resonance imaging and interventional procedures. Thieme, Stuttgart, 1997, 265–269.

[5] Guillot E, Couturaud B, Reyal F, Curnier A, Ravinet J, Laé M, Bollet M, Pierga JY, Salmon R, Fitoussi A; Breast Cancer Study Group of the Institut Curie. Management of phyllodes breast tumors. Breast J, 2011, 17(2):129–137.

[6] Feder JM, de Paredes ES, Hogge JP, Wilken JJ. Unusual breast lesions: radiologic-pathologic correlation. Radiographics, 1999, 19(Spec No):S11–S26; quiz S260.

[7] Harvey JA. Unusual breast cancers: useful clues to expanding the differential diagnosis. Radiology, 2007, 242(3):683–694.

[8] Ben Hassouna J, Damak T, Gamoudi A, Chargui R, Khomsi F, Mahjoub S, Slimene M, Ben Dhiab T, Hechiche M, Boussen H, Rahal K. Phyllodes tumors of the breast: a case series of 106 patients. Am J Surg, 2006, 192(2):141–147.

[9] Tan PH, Thike AA, Tan WJ, Thu MM, Busmanis I, Li H, Chay WY, Tan MH; Phyllodes Tumour Network Singapore. Predicting clinical behavior of the breast phyllodes tumours: a nomogram based on histological criteria and surgical margins. J Clin Pathol, 2012, 65(1):69–76.

[10] Ang MK, Ooi AS, Thike AA, Tan P, Zhang Z, Dykema K, Furge K, Teh BT, Tan PH. Molecular classification of breast phyllodes tumors: validation of the histologic grading scheme and insights into malignant progression. Breast Cancer Res Treat, 2011, 129(2):319–329.

[11] Liberman L, Bonaccio E, Hamele-Bena D, Abramson AF, Cohen MA, Dershaw DD. Benign and malignant phyllodes tumors: mammographic and sonographic findings. Radiology, 1996, 198(1):121–124.

[12] Chao TC, Lo YF, Chen SC, Chen MF. Sonographic features of phyllodes tumors of the breast. Ultrasound Obstet Gynecol, 2002, 20(1):64–71.

[13] Yabuuchi H, Soeda H, Matsuo Y, Okafuji T, Eguchi T, Sakai S, Kuroki S, Tokunaga E, Ohno S, Nishiyama K, Hatakenaka M, Honda H. Phyllodes tumor of the breast: correlation between MR findings and histologic grade. Radiology, 2006, 241(3): 702–709.

[14] Yoo JL, Woo OH, Kim YK, Cho KR, Yong HS, Seo BK, Kim A, Kang EY. Can MR Imaging contribute in characterizing well-circumscribed breast carcinomas? Radiographics, 2010, 30(6): 1689–1702.

[15] Yilmaz E, Sal S, Lebe B. Differentiation of phyllodes tumors *versus* fibroadenomas. Acta Radiol, 2002, 43(1):34–39.

[16] Irshad A, Ackerman SJ, Pope TL, Moses CK, Rumboldt T, Panzegrau B. Rare breast lesions: correlation of imaging and histologic features with WHO classification. Radiographics, 2008, 28(5):1399–1414.

[17] Chung EM, Cube R, Hall GJ, González C, Stocker JT, Glassman LM. From the archives of the AFIP: breast masses in children and adolescents: radiologic-pathologic correlation. Radiographics, 2009, 29(3):907–931.

[18] Bode MK, Rissanen T, Apaja-Sarkkinen M. Ultrasonography and core needle biopsy in the differential diagnosis of fibroadenoma and tumor phyllodes. Acta Radiol, 2007, 48(7): 708–713.

[19] Jorge Blanco A, Vargas Serrano B, Rodríguez Romero R, Martínez Cendejas E. Phyllodes tumors of the breast. Eur Radiol, 1999, 9(2):356–360.

[20] Choi J, Koo JS. Comparative study of histological features between core needle biopsy and surgical excision in phyllodes tumor. Pathol Int, 2012, 62(2):120–126.

[21] Jang JH, Choi MY, Lee SK, Kim S, Kim J, Lee J, Jung SP, Choe JH, Kim JH, Kim JS, Cho EY, Lee JE, Nam SJ, Yang JH. Clinicopathologic risk factors for the local recurrence of phyllodes tumors of the breast. Ann Surg Oncol, 2012, 19(8): 2612–2617.

[22] Dillon MF, Quinn CM, McDermott EW, O'Doherty A, O'Higgins N, Hill AD. Needle core biopsy in the diagnosis of phyllodes neoplasm. Surgery, 2006, 140(5):779–784.

[23] Rowell MD, Perry RR, Hsiu JG, Barranco SC. Phyllodes tumors. Am J Surg, 1993, 165(3):376–379.

[24] Tsang AK, Chan SK, Lam CC, Lui PC, Chau HH, Tan PH, Tse GM. Phyllodes tumours of the breast – differentiating features in core needle biopsy. Histopathology, 2011, 59(4): 600–608.

[25] Goel NB, Knight TE, Pandey S, Riddick-Young M, de Paredes ES, Trivedi A. Fibrous lesions of the breast: imaging–pathologic correlation. Radiographics, 2005, 25(6): 1547–1559.

[26] Barrio AV, Clark BD, Goldberg JI, Hoque LW, Bernik SF, Flynn LW, Susnik B, Giri D, Polo K, Patil S, Van Zee KJ. Clinicopathologic features and long-term outcomes of 293 phyllodes tumors of the breast. Ann Surg Oncol, 2007, 14(10): 2961–2970.

[27] Tan PH, Jayabaskar T, Chuah KL, Lee HY, Tan Y, Hilmy M, Hung H, Selvarajan S, Bay BH. Phyllodes tumors of the breast: the role of pathologic parameters. Am J Clin Pathol, 2005, 123(4):529–540.

[28] Bhargav PR, Mishra A, Agarwal G, Agarwal A, Verma AK, Mishra SK. Phyllodes tumour of the breast: clinicopathological analysis of recurrent *vs.* non-recurrent cases. Asian J Surg, 2009, 32(4):224–228.

[29] Fajdić J, Gotovac N, Hrgović Z, Kristek J, Horvat V, Kaufmann M. Phyllodes tumors of the breast diagnostic and therapeutic dilemmas. Onkologie, 2007, 30(3):113–118.

[30] Yohe S, Yeh IT. “Missed” diagnoses of phyllodes tumor on breast biopsy: pathologic clues to its recognition. Int J Surg Pathol, 2008, 16(2):137–142.

[31] Hajdu SI, Espinosa MH, Robbins GF. Recurrent cystosarcoma phyllodes: a clinicopathologic study of 32 cases. Cancer, 1976, 38(3):1402–1406.

Corresponding authors

Lucia Georgeta Daina, Associate Professor, MD, PhD, Department of Neurosciences, Faculty of Medicine and Pharmacy, University of Oradea, 10 1 Decembrie Square, 410068 Oradea, Bihor County, Romania; Phone +40771–255 673, e-mail: lucidaina@gmail.com

Adriana Nicoleta Pirte, Associate Professor, MD, PhD, Department of Dentistry, Faculty of Medicine and Pharmacy, University of Oradea, 10 1 Decembrie Square, 410068 Oradea, Bihor County, Romania; Phone +40722–467 422, e-mail: pirte_adriana@yahoo.com

Received: February 4, 2015

Accepted: December 15, 2015